

---

# FACILITATION OF BOMA ADAPTATION OF AN INJURED SUBADULT MALE SOUTHERN WHITE RHINOCEROS *Ceratotherium simum simum* VIA INTRODUCTION TO AN ADULT MALE

Steven A. Osofsky<sup>1</sup>, Peter S. Rogers<sup>2</sup> and Andrew Trawford<sup>3</sup>

<sup>1</sup> Botswana Department of Wildlife and National Parks, PO Box 131, Gaborone, Botswana (current address: Director, Animal Health Services, Fossil Rim Wildlife Center, PO Box 2189, Rt.1 Box 210, Glen Rose, Texas, 76043 USA)

<sup>2</sup> Natal Parks Board, PO Box 456, Mtubatuba 3935, South Africa

<sup>3</sup> Botswana Department of Animal Health and Production, PO Box 64, Serowe, Botswana

## ABSTRACT

A rhino operation in Botswana led to the capture and translocation of four southern white rhinoceros, *Ceratotherium simum simum*. At the time of capture, an approximately three to four year-old bull was found to have three recent bullet wounds. Internal injuries that may have resulted from the wounds could not be adequately assessed. All four animals, including the injured bull, were judged to be in good body condition at the time of capture and translocation to holding bomas. The subadult bull refused to eat any significant quantity of food offered, even after ten days in captivity. He appeared to be seeking social interaction - vocalising and rubbing against the fence between himself and the adult bull. The gate between the two bulls' bomas was opened 12 days after the young bull's capture. The young bull's overall attitude improved, he charged the fence much less, and he followed the old bull around constantly and started to eat. The two animals were frequently in bodily contact. The adult bull tolerated the young bull relatively well. Nevertheless, the young rhino died six days after the introduction of the adult bull, despite veterinary intervention for suspected wound-related sepsis. The animal's death from bullet wound-related injuries should not detract from the positive behavioural responses elicited by the companionship of the adult bull.

## INTRODUCTION

By the early 1900's the population of southern white rhinoceros, *Ceratotherium simum simum*, was wiped out everywhere except in Natal, primarily because of human predation and competition for resources (Estes, 1991). Desiccating climatic changes may have also played a role (Hitchins, 1992). Between 1967 and 1982, a total of 94 white rhinos were reintroduced from Natal

into protected areas of northern Botswana (Hitchins, 1992). At least 12 white rhinos were known to have been poached in northern Botswana since October 1992. In February 1993 the Botswana Department of Wildlife and National Parks asked the Natal Parks Board Rhino Capture Team to assist them in the capture of whatever remaining rhino could be located in northern Botswana for translocation to a privately developed sanctuary in east-central Botswana. The heavy poaching pressure near Botswana's northern and eastern international borders, combined with the sighting of only seven white rhinos on an aerial survey in September/October 1992 (Hitchins, 1992), prompted the rhino rescue operation.

## CASE STUDY

On 12 February, the first two animals were caught: a cow believed to be approximately 30 years old and her approximately nine-month old calf. The cow had an ear notch in her left ear, and was believed to have been one of the animals introduced from Natal's Umfolozi Game Reserve. These two animals were transported in separate crates to the Khama Rhino Sanctuary in Serowe, where they were released together into holding boma number one (see Figure), 22 hours post-capture. They were from a group of three originally spotted from the air. The third animal, an approximately 30 year-old bull (also with an ear notch and a hole from an ear tag in his right ear), was captured on 15 February in the same general area. The bull was released into his own holding boma, number two, at the Sanctuary 14 hours later.

The final animal to be caught was a three to four-year old bull. He was found on his own, approximately 20km from where the other animals were caught. At the time of capture, this animal had three bullet wounds estimated to be approximately seven to ten days old. One wound was in the right shoulder, one was in the skull above

the frontal sinus, and the third consisted of an entry and exit wound below the right ear near the angle of the mandible. All wounds were cleaned and flushed with commercial bovine intramammary antibiotic preparations (procaine penicillin/ dihydrostreptomycin and potassium penicillin/ procaine penicillin/neomycin). In addition, intramuscular procaine/benzathine penicillin as well as amoxicillin/colistin sulphate were administered. The young bull was released uneventfully into his own boma, number three, at the Sanctuary 18 hours later on the morning of 16 February. All four animals, including the injured bull, were judged to be in good body condition at the time of capture.

Post-capture loss of appetite is potentially a lifethreatening problem for free ranging white rhinos put into bomas, especially older bulls, with animals often not feeding for the first seven to ten days (or longer) post-capture (Rogers, 1993). Ideally, bomas should be situated so that anorectic animals can be released back into the field if no evidence of feeding is seen within this period. Such animals often start grazing almost immediately after they are out of the boma. In the case of this project, security concerns

precluded building holding facilities in actual rhino habitat in northern Botswana. In addition, the Khama Rhino Sanctuary was still in the process of trying to raise funds for a perimeter fence, so the only option for release from a boma would be to allow the animal into a slightly larger paddock (refer to Figure). Note that paddock facilities were not utilised for the period covered by this report.

The Sanctuary bomas, with walls two metres in height, are constructed of 15-22cm diameter tanelite-treated poles, spaced approximately 15cm apart. All bomas have water troughs which are kept full, clay-lined wallowing points, as well as appropriate natural and artificial shade. Paddocks are comprised of five strands of 25cm diameter steel mining cable (spaced from the ground at 10cm, 30cm, 30cm, 40cm, and 40cm) strung through steel railway tracks spaced every 20m. Each three metre long rail is sunk one metre into concrete. The initial plan included 19 seven to ten centimetre diameter droppers spaced evenly between every two railway lines in the paddock walls. Larger poles were planted into the ground every 5m to strengthen the walls.

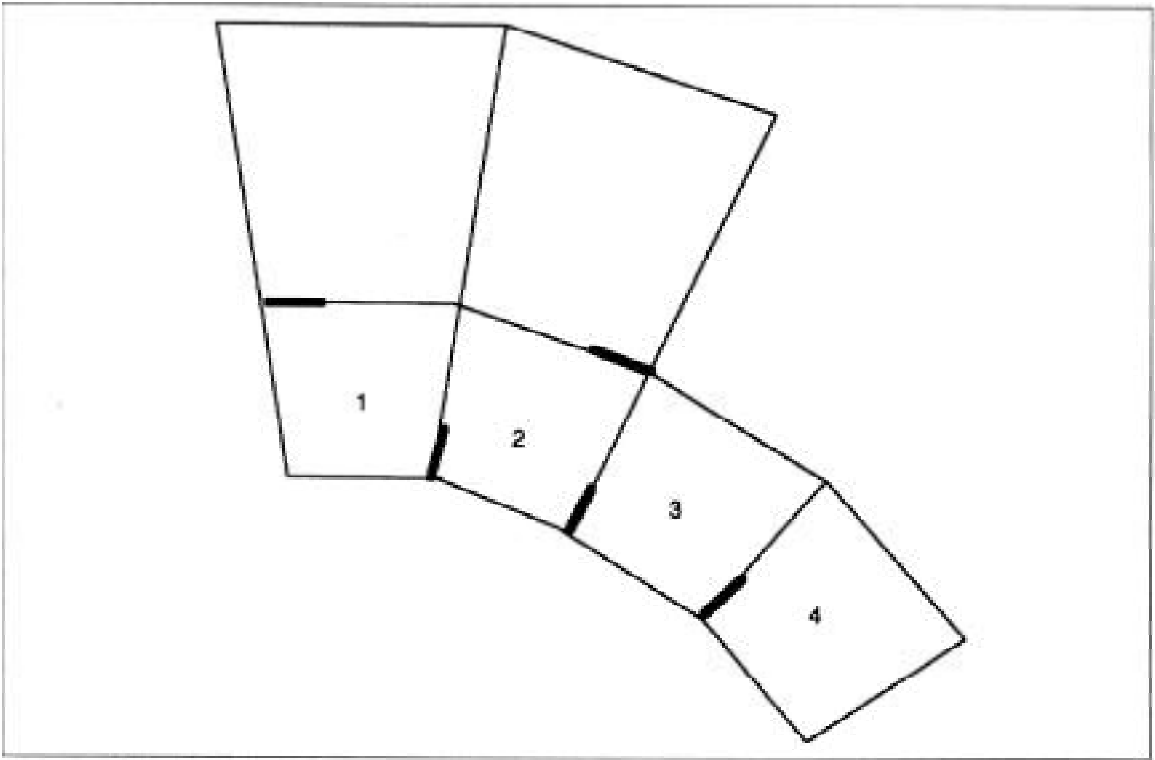


Figure. Khama Rhino Sanctuary bomas ito 4 and paddocks (not to scale). The front of the bomas are at the bottom of the diagram. The front of each boma is five metres long. The side walls of each paddock are 80m long. The back wall of each paddock is 80m across. Internal gates are indicated by bold lines.

---

All animals except the subadult bull were eating and drinking fairly well within one week of being placed into the bomas. The cow started eating by day four post-capture, with the calf suckling within 24 hours of release into the boma. The adult bull was eating by day six post-capture. They were being fed grass freshly cut locally, consisting of a mixture of predominantly *Eragrostis*, *Panicum*, and *Digitaria* species. These were initially supplemented with grasses cut in Chobe National Park. By day ten, the subadult bull had only taken a few bites of grass. Attempts at offering the animal a variety of fresh fruits, teff hay, lucerne hay, as well as grass covered with molasses were unsuccessful. The rhino was, however, seen to drink several times per day.

This young animal appeared to be seeking social interaction by vocalising and rubbing against the fence between himself and the adult bull. The subadult bull's predominant vocalisations were classified (Estes, 1991) as whining (juvenile begging call) and squeaking (juvenile in distress). The only animal that seemed to pay much attention to these sounds was the young female calf, who would sometimes look in the direction of the sound. The subadult bull was the most aggressive animal in the bomas. He often charged the walls of the boma when approached by caretakers. It should be noted that ground surveillance in the area where the young bull was captured revealed that he had been traveling in a group with at least two other animals. A week before the capture operation began, an adult cow and a female calf were found to have been poached in the area. Combining the spoor findings and the estimated age of this animal's bullet wounds, it seems quite likely that the poached animals were the young bull's mother and younger sibling.

Given the history, age, and general behaviour of this subadult bull, it was felt that the problem observed was most likely not the "classic" confinement-related inappetence of the white rhinoceros (Rogers, 1993). In addition, internal injuries that may have resulted from the three bullet wounds could not be adequately assessed. The decision was made not to give the young bull access to a paddock, as it was felt this would only serve to isolate him further from the other animals. In addition, the rearrangements necessary to achieve this might have disrupted the otherwise smooth boma adaptation process in the other three animals. Thus, paddocks were kept closed off.

As it was felt that a lack of social interaction was contributing to the overall stress the young bull was experiencing, the gate between the two bulls' bomas

was opened on 27 February - 12 days after the young bull's capture. This was a novel yet potentially dangerous approach to the problem of appetite loss. Normally, wild-caught white rhinos believed to come from different social groups are not penned together, especially if they are the same sex (Booth and Coetsee, 1988) and of disparate sizes. The young bull was approximately seven-tenths the size of the adult bull.

The plan seemed to work initially. No aggression was manifested as the young bull crossed over into the adult bull's boma. During the course of the first day, the young bull's overall attitude improved; he charged the fence much less, and he followed the old bull around constantly. He watched the old bull eating, and then he too started to eat. Progress was rapid. The young bull continued to drink regularly. The young bull would often lie adjacent to the adult bull during rest periods. The two animals were frequently in bodily contact when standing. The adult bull tolerated the young bull relatively well, only occasionally gently horned him in the axillary region. Such antagonistic behaviour was generally confined to times when new feed was placed into the boma, or when both animals tried to drink simultaneously at the water trough, which was too small to accommodate both of them comfortably.

The young rhino continued to eat small amounts during the next day, 28 February. On 1 March he again ate a small amount and defaecated. However, on 2 March the young bull appeared weak and depressed. As the possibility of bullet wound-related sepsis could not be ruled out, that evening the young bull was started on broad spectrum antibiotics. He was given enrofloxacin by intramuscular darts. As the animal had received high doses of intramuscular antibiotics at the time of capture (with his wounds flushed with topically active antibiotics), ongoing antibiotic therapy had not been instituted in the bomas. Systemic antibiotics in a wild anorectic rhinoceros need to be administered with large volume darts, and the disturbance this would cause was not desirable during the early boma training period without clear justification. The fact that the rhino started to eat and then stopped again is what altered our perspective and prompted more specific therapeutic intervention. On the same day, the drinking water was supplemented with dextrose, sucrose, and a commercial B-complex vitamin syrup.

On the morning of 3 March, the drinking water was supplemented with appropriate amounts of electrolytes in the form of sodium chloride and potassium chloride. That evening, a second dose of enrofloxacin was given.

On Thursday 4 March, the rhino was still not doing well. He had not, as far as could be determined without night-vision equipment, been eating any significant amounts of feed. The decision was made that day to immobilise him with a very low dose of etorphine hydrochloride in order to implement supportive veterinary measures: 1. stomach-tubing of a calorically dense multi-source carbohydrate/amino acid/vegetable oil/vitamin/electrolyte mixture; 2. administration of intravenous fluids, as well as the administration of intramuscular antibiotics, B-complex vitamins, vitamin E, and selenium. Due to his debilitated state, the rhino was kept on intranasal oxygen during the procedure with continuous real-time pulse oximetry monitoring. He recovered without complication from this procedure, walking away less than two minutes after the naloxone/naltrexone/narcotic/antidotes were given. Nevertheless, the rhino died at 5pm the next day. Necropsy revealed that the bullet which had entered the right shoulder had passed through the thoracic and abdominal cavities, leading to diffuse pleuritis and peritonitis, which was confirmed histopathologically. Examination of the bullet recovered from the abdomen revealed that it was of a 7.62mm calibre, with a 39 Russian casing, fired from an AK-47 or an SKS semiautomatic weapon, according to the Botswana Department of Wildlife and National Parks Anti-Poaching Unit.

## CONCLUSION

The fact that this animal died from bullet wound-related injuries should not detract from the positive behavioral responses that companionship of the adult

bull seems to have elicited. The authors were unable to find any similar cases of such an intentional introduction of two captive white rhino bulls documented in the literature.

## ACKNOWLEDGEMENTS

The authors would like to thank the management and staff of the Khama Rhino Sanctuary for all their assistance during this difficult period.

## REFERENCES

Booth, V.R. & Coetsee, A.M. (1988) The capture and relocation of black and white rhinoceros in Zimbabwe. In: *Translocation of Wild Animals*. (ed.) L. Nielsen and R.D. Brown. Wisconsin Humane Society and the Caesar Kleberg Research Institute, USA.

Estes, R. D. (1991) *The Behavioral Guide to African Mammals*. The University of California Press, Berkeley.

Hitchins, P.M. (1992) An aerial census of black and square-lipped rhinoceros in northern Botswana, 18 September - 2 October, 1992. Rhino and Elephant Foundation Report to the Botswana Department of Wildlife and National Parks.

Rogers, P.S. (1993) Care of the white rhinoceros *Ceratotherium simum in captivity*. In: *The Capture and Care Manual* (ed.) A. A. McKenzie. Wildlife Decision Support Services CC and the South African Veterinary Foundation, Pretoria.

Photo credit: Kes and Fraser Smith



A female northern white rhinoceros with her calf, Garamba National Park, Zaire.