

---

# STANDARDISED BODY CONDITION SCORING SYSTEM FOR BLACK RHINOCEROS (*DICEROS BICORNIS*)

<sup>1</sup> Hans - O Reuter and <sup>2</sup> Keryn Adcock

<sup>1</sup> Save the Rhino Trust, P. O. Box 224, Swakopmund, Namibia

<sup>2</sup> Consultant, Wild Solutions, Box 1212, Hilton, 3245, South Africa

## ABSTRACT

The body condition scoring system for black rhinoceros (*Diceros bicornis*), which has been described by Reuter, H.O. and Horspool, L.J.I. (1996) has been modified. More detailed descriptions of seven body regions to be assessed and pictures which show the specific characteristics of each body condition score have been included in this simple descriptive 5-point scale for assessing black rhino condition. The aim is to minimise assessor bias and thus provide a standardised, reliable and repeatable body condition scoring system for black rhino.

## RESUME

Le système d'enregistrement basé sur la condition du corps du rhinocéros noir (*Diceros bicornis*), décrit par Reuter et Horspool (1996) a été modifié. Des descriptions plus détaillées sur sept régions du corps ont été évaluées et les tableaux obtenus présentent des caractéristiques spécifiques de chaque condition du corps enregistré, en incluant cette simple description à l'échelle 5 - point pour évaluer la condition du rhinocéros noir. Le but visé est de minimiser les erreurs de l'évaluateur et fournir un système d'enregistrement de la condition du corps qui soit fiable, standardisé, de dont la répétition est possible.

---

## INTRODUCTION

When an animal is losing condition, the fat reserves are mobilised and then muscle wasting sets in to supply the required energy demand. Body condition scoring assesses the amount of subcutaneous fat and the degree of muscling. This will reflect changes in body weight and provide an estimate of nutritional status and fitness. The average condition among animals indicates the response of a population to prevailing environmental conditions. However, behaviour and sex-based differences between individuals also affect condition. For example, nutritional demands on females increase greatly during late pregnancy and lactation, and such females are often the first to lose condition when food limitations arise.

In animal management, many important decisions, e.g. the provision of supplementary feed, are based on the assessment of body condition. In game species, the assessment of body condition during boma confinement and in the initial post-release period provides an indication of the response of an animal to the translocation and its new environment. In black rhino, loss of body condition is often the only indication of chronic disease. Resistance to disease, drought and frost are also related to an animal's condition. Moreover, there is evidence that mammals may require a minimum level

of body fat for adequate reproductive performance. The provision of a standardised, reliable body condition scoring system for black rhino will enable management to be optimised and increase the speed at which several problems can be detected.

During 1996 a study has been conducted in Namibia by H.-O. Reuter and L.J.I. Horspool, during which a simple descriptive 5-point scale for assessing condition over several body regions of black rhino has been statistically tested for the repeatability and agreement between observers. The results of this study have been published in a paper presented at the Joint 50<sup>th</sup>, Anniversary Congress of the Namibian Veterinary Association and 2<sup>nd</sup> Africa Scientific Congress of the World Veterinary Association, 10-12th September 1997, Swakopmund, Namibia. (Assessing body condition using observable criteria in free-ranging black rhinoceros, *Diceros bicornis bicornis*. Reuter, H.O. and Horspool, L.J.I.)

The most repeatable use of the scale was by calculation combined scores given to the various body regions by an observer. During the study it was apparent, that the subjectivity of a descriptive scale scoring system led to assessor bias, i.e. a tendency for some assessors to score consistently high or low.

More detailed description of the body regions to be assessed and better pictures to illustrate the specific characteristics of each body condition score will help to minimise such assessor bias, thus providing a standardised, reliable and repeatable body condition scoring system for black rhino.

## **DESCRIPTION OF BODY REGIONS TO BE OBSERVED WHEN ASSESSING BODY CONDITION IN BLACK RHINO**

### **The neck**

The rhino neck has a complex set of muscles between the back of the head to the rhino's withers, shoulders and chest, allowing the wide range of movements necessary for moving the head during feeding, and lifting and balancing the forequarters while walking or running. The nuchal ligament runs along the top of the neck from head to withers, above the neck vertebrae which are more deeply embedded in the neck. This muscle and ligament structure means the neck can change greatly in appearance, providing a useful measure of condition.

- When black rhino are in good body condition the neck region appears thick across the top, and is well muscled, with a smooth gradation between it and the shoulder blade. It must be noted that adult rhino bulls have a thicker (more muscled) neck than female rhino.
- As body condition deteriorates and muscle wasting sets in the neck region becomes narrower and flattened in appearance. The muscles hollow out in front of the shoulder blade, so that a prescapular groove develops.
- Eventually the -nuchal ligament, back of the skull (occipital bone) and in very emaciated rhino the cervical (neck) vertebra become visible.
- (Neck muscles include the cervical part of the trapezius, splenius, cervical serratus, rhomboideus, complexus and the brachiocephalic muscles.)

### **The shoulder (scapular) region**

- The scapular (shoulder-blade) with its spine is a prominent bony feature in the shoulder region.
- When a rhino is in good condition, this area is well covered by the infra- and supraspinatus, the deltoid and the trapezius muscles, and the subcutaneous fat layer under the thick skin.
- The rounded appearance of the shoulder changes by a flattening of the region, as body condition deteriorates.

- The spinous process of the scapula and eventually the leading (anterior) edge of the scapula become more sharply defined, and the muscled areas appear concave in front of and behind the scapular spine as body condition worsens.

### **The ribs (costal region)**

- When rhino are in excellent condition the ribs are covered with thick skin folds, especially just behind the shoulder and elbow region.
- As the subcutaneous fat reduces in thickness, the ribs become visible and with further loss in condition increasingly more noticeable.

### **The spine (vertebral region)**

The spinous processes of the vertebra are covered along the top (dorsally) by the supraspinal ligament and on either side by the longissimus dorsi muscles.

- The vertebral region appears rounded and the long back muscle and fat deposits fill the gap between the ribs and the spine, if black rhino are in excellent condition.
- As the subcutaneous fat layer is lost the supraspinal ligament, which covers the spinous processes become visible as a defined line.
- Due to wasting of the longissimus dorsi muscles, the back hollows out either side of the spine, which become progressively more obvious. Eventually the costal processes of the vertebrae become visible.

### **The rump (gluteal region)**

The bony protuberances of the pelvis, namely the tuber coxae, the tuber sacrum and tuber ischiadicum, and the major trochanter of the femur along with the surrounding gluteal and biceps femoris muscles are good indicators of a rhino's condition.

- If a rhino is in excellent condition this region appears rounded and the bony points are covered.
- The rump starts to hollow out quite early on during loss of condition, and the bony points become visible as a rhino is losing condition.
- As condition worsens, the bony protuberances become increasingly prominent and the muscled region eventually appears markedly concave, with ropy ligaments and muscle strands showing under the skin.

### **The abdominal region**

- The abdomen appears filled and taught when a rhino is in good condition.
- As a rhino is losing condition, the abdomen becomes

Table 1. Descriptions of the appearance of each of the assessment sites at different body conditions in black rhino (modified from Reuter and Horspool, 1996).

CONDITION Assessment site	Numerical scale Descriptive scale	5 excellent (heavy)	4 good (ideal)	3 fair (average)	2 poor (thin)	1 very poor (emaciated)
A Neck	General appearance	thick, well muscled, rounded	well muscled, rounded	rounded	flat, narrow neck; nuchal ligament visible	narrow, angular (bony) neck; nuchal ligament prominent
	Prescapular groove		-	slightly visible	obvious	deep groove very obvious
B Shoulder	General appearance	well-muscled, rounded	rounded	flat	flat, slightly angular (bony)	angular, bony
C Ribs	Scapula	covered	covered	spine visible	obvious	very obvious
		well covered (skin folds)	covered (skin folds)	visible	obvious	very obvious
D Spine	General appearance	rounded	slightly angular	back groove back visible	groove deep obvious	back groove very obvious
	Spinous processes	covered	slightly visible	visible	prominent	very prominent
E Rump	General appearance	well rounded	flattened	slightly concave	concaveobvious depression	
	Bony protuberances	covered	slightly visible	visible	prominent	very prominent
F Abdomen	General appearance	distended, taught	filled	slightly tucked in	tucked in	tucked in
	Flank-fold	none	sometimes slightly visible	slightly visible	visible	obvious
G Tail base		rounded (bulging)	rounded	narrow	slightly bony	very thin and bony

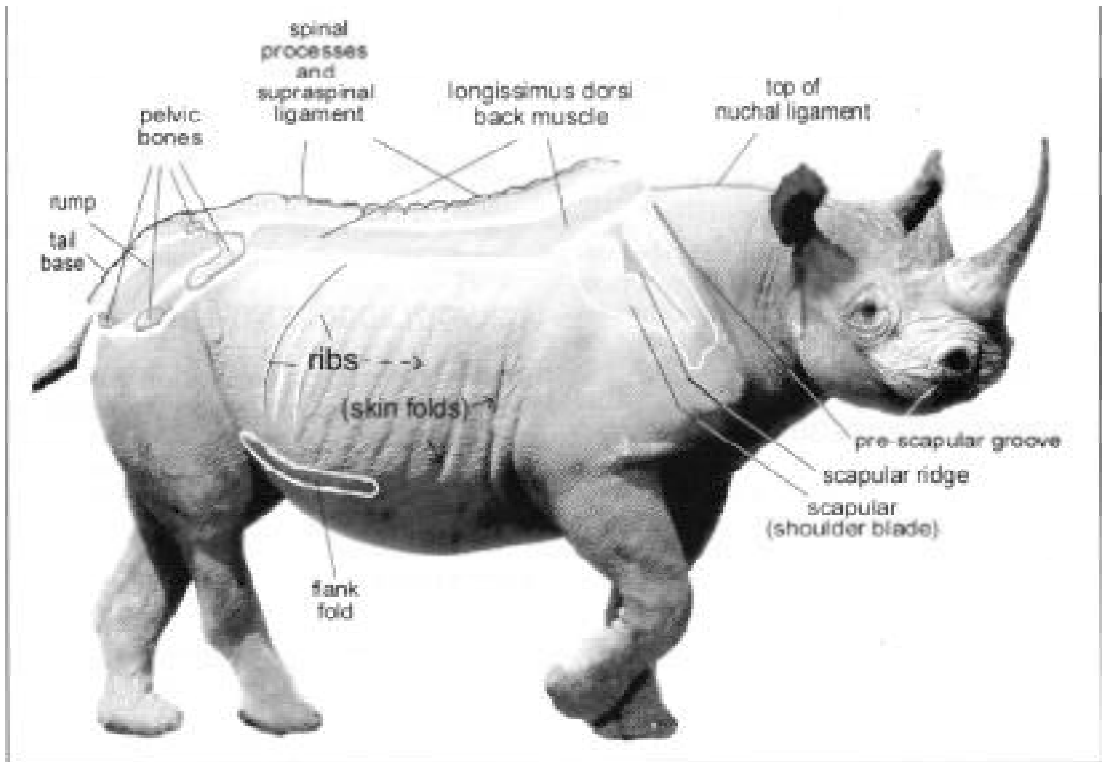



Figure 1. The body regions and specific anatomical features to be observed when assessing a rhino's condition.



Figures 2. The appearance of black rhino for all body condition scores.

tucked in and a skin fold in the flank becomes visible. During a period of anorexia this flank-fold also becomes prominent, even 'though the rhino has not otherwise lost condition noticeably. This suggests that the fullness of the intestinal tract and the state of hydration influence the prominence of the flank-fold.

### The tail-base (caudal region)

The amount of subcutaneous fat around the tail-base can help to indicate how good a rhino's condition is. From forming a broad swelling up to the spine, this area narrows and appears more and more bony and raised above the rump, as condition deteriorates.

### ASSESSMENT PROCEDURE

- Satisfactory condition scoring can only be achieved if an undisturbed rhino is viewed from its side at close range (not more than 100 metres away) in the open using binoculars. The quality of light is important for reliable assessment and preferably the rhino must be viewed slightly back-lit (early morning or late afternoon), so that any bony prominence become noticeable through the contrast revealed by their shadows.
- The most reliable and repeatable body condition scoring will be achieved by assessing all the regions separately, giving a score (1-5) using unit increments to each region and then combining these scores or calculating their average.
- It may be useful to observe other body regions as well. For standardised, repeatable assessment, however, the side view of the above mentioned regions was found to be most reliable.
- Frequently rhino may, however, present facing the observer or run away before assessment of all sites is completed. Sometimes not all assessment regions are visible, e.g. when rhino are found in thick bush. Also, rhino in a boma are frequently viewed from an elevated position and rhino seen from an aircraft are viewed at an angle from above. Even if only some of the above body regions and their characteristics can be assessed during a rhino observation, some indication of the rhino's body condition will be gained.
- Observers trained to assess condition by applying the described method, will usually find it easier

than untrained people to get some indication of a rhino's body condition, even if conditions for observation are not optimal. The reliability and repeatability of such observations can be assumed to be less consistent, however, than assessment of all the regions under optimal condition. Therefore, whenever possible efforts should be made to view rhino under optimal conditions when assessing their body condition.

### ACKNOWLEDGEMENTS

The authors would like to thank R. Brett, R. du Toit, R. Emsley, B. Loutit and P. Morkel for their constructive input towards this paper and for sharing their valuable field experience in assessing condition of rhino with the authors. The original rhino picture adapted for this work is from Penny (1987)6.

### REFERENCES

- Adcock, K. 1998. About black rhino, Notes for WWF course for Kenyan rhino officers, Wild Solutions.
- Bothma, J. du P. 1986. In, *Wildploegasbestuur*, 1st Edition, J.L. van Schaik, RSA, 164-168.
- Brett, R. 1998. Personal communication, Consultant, Scotland.
- du Toit, R. 1998. Personal communication, Lowland conservancies, Zimbabwe.
- Emsley, R. 1998. Personal communication, Scientific coordinator, African Rhino Specialist Group, South Africa
- Keep, M. E. 1971. Observable criteria for assessing the physical condition of the white rhinoceros *Ceratotherium simum* in the field, *Lammergeyer* 13,25-28.
- Laflamme, D.P. 1993. Body Condition scoring and weight maintenance, Proceedings: North American Veterinary Conference, January 1993, Orlando, 290-291.
- Loutit, B. 1998. Personal communication, Save the Rhino Trust, Namibia

- Morkel, P. 1998. Personal communication, National Park Board, South Africa.
- Penny, M. 1987. Rhinos - Endangered Species, Christopher Helm, Ltd., Kent.
- Popesko, P. 1979. Atlas of topographical anatomy of the domestic animals. WB. Saunders Company Philadelphia, London, Toronto. Vol. I pp. 161-165; Vol II pp. 127, 146-150; Vol. III pp. 146- 150.
- Reuter, H.-O. and Horspool, L.J.I. 1996. Assessing body condition using observable criteria in free-ranging black rhinoceros (*Diceros bicornis bicornis*). Proceedings: Joint 50<sup>th</sup> Anniversary Congress of the Namibian Veterinary Association and 2<sup>nd</sup> Africa Scientific Congress of the World Veterinary Association, 10-12<sup>th</sup> September 1997, Swakopmund, Namibia. pp 45-54.